

Improved Upper Blepharoplasty Outcome Using an Internal Intradermal Suture Technique: A Prospective Randomized Study

SHARISELLE M. W. POOL, MD,* IRENE S. KRABBE-TIMMERMAN, MD,[†] MICHEL CROMHEECKE, MD, PhD,[‡] AND BEREND VAN DER LEI, MD, PhD*[‡]

OBJECTIVE To assess whether a suture technique in upper blepharoplasty may be the cause of differences in the occurrence of suture abscess formation and focal inflammation.

MATERIALS AND METHODS A Level I, randomized controlled trial. The upper blepharoplasty wound was closed with a running intradermal suture. External intradermal suturing implied that this suture was started by initially passing it through the intact skin adjacent to the wound. In contrast, internal intradermal suturing meant the intradermal suture was not started in the adjacent skin but simply within the wound itself. One week and 6 weeks after surgery, the presence of suture abscesses and focal inflammation was assessed at the entrance and exit of the sutures.

RESULTS After 1 week, 12 abscesses (40.0%) were found at the medial side of the externally sutured upper eyelids and 4 abscesses (13.3%) in the internally sutured upper eyelids ($p = .02$). The presence of erythema and edema after 1 week was also significantly lower in internally sutured upper eyelids ($p = .02$).

CONCLUSION In this series, the method of starting the suture (internal vs external) at the medial side of an upper blepharoplasty wound was associated with a statistically significant reduction in the incidence of medial wound inflammation and suture abscess formation at a 1-week follow-up.

The authors have indicated no significant interest with commercial supporters.

Upper blepharoplasty is a frequently performed surgical procedure. At the end of the procedure, the skin is usually closed with very fine sutures that are removed after 5 to 7 days. In the authors' practice, they mostly use a continuous intradermal (subcuticular) suture with nylon 6-0 for closure, which can easily be removed after 1 week.

Inflammation associated with an upper blepharoplasty closure, including erythema, swelling, and suture abscess formation, is a minor complication that is commonly seen to affect the medial aspect of the incision at a 1-week follow-up visit.¹⁻³ It struck the authors that most of their colleagues had a high incidence of medial incision inflammation at the 1-week visit with

the exception of the senior author (B.v.d.L.). The main difference between these colleagues and the senior author was the method used to start a subcuticular closure. The suture was either introduced through the intact adjacent skin before entering the wound for the subcuticular closure (external intradermal suturing) or it was introduced through the wound margins directly without first penetrating through the intact adjacent skin, the method used by the senior author. In the latter situation, it was the authors' impression that suture inflammation was infrequent. Although the inflammation often resolves spontaneously or is easily managed,¹⁻³ suture inflammation, with erythema, swelling, and abscess formation, is a concern for patients that is best avoided.

*Department of Plastic Surgery, University Medical Center Groningen, the Netherlands; [†]Department of Plastic Surgery, Medical Center Leeuwarden, the Netherlands; [‡]Private Clinic for Aesthetic Surgery, Bergman Clinics Heerenveen, the Netherlands

© 2015 by the American Society for Dermatologic Surgery, Inc. Published by Wolters Kluwer Health, Inc. All rights reserved.
ISSN: 1076-0512 • Dermatol Surg 2015;41:246-249 • DOI: 10.1097/DSS.0000000000000245

Based on these observations, the authors hypothesized that postoperative medial wound inflammation and suture abscess formation could be controlled by a measure as simple as how the suture is introduced into the skin for wound closure. The authors report here their prospective randomized study designed to answer this question.

Materials and Methods

During a period of 6 months, the authors asked all patients between 25 and 75 years of age who were planned for upper blepharoplasty, to participate in this study. Patients with previous blepharoplasties, connective tissue disorders, or diabetes, and patients using anticoagulants or anti-inflammatory drugs, were excluded. The study received approval from the Medical Ethical Committee of the Medical Center Leeuwarden, the Netherlands. Written informed consent was obtained from all participants.

Bipolar Coagulation-assisted Orbital septoblepharoplasty⁴ was performed in all patients. Before the operation, the design of the incision lines was marked with a waterproof pencil. The operation was usually performed under local anesthesia after the skin had been disinfected. Skin infiltration was performed with lidocaine 2% (Xylocaine; AstraZeneca BV, Zoetermeer, the Netherlands) with 1:100,000 epinephrine. After skin incision with a scalpel, the skin and subcutaneous layer were dissected with scissors. Next, a very small rim of the preseptal orbicularis muscle was removed, after which the orbital septum was exposed. Meticulous hemostasis was performed using bipolar coagulation. During the operation, bipolar coagulation of the exposed septum orbitale was performed resulting in shrinkage of the septum and thus repositioning the bulging subseptal fat.

Finally, the wound was closed with a running intradermal 6-0 nylon pullout suture (Ethilon; Ethicon, Sint-Stevens-Woluwe, Belgium). On 1 upper eyelid, the subcuticular suture started and ended within the confines of the incision without the needle being passed through the adjacent intact skin (internal intradermal suturing) (Figures 1A and 2). On the other upper eyelid, the subcuticular suture was

started outside the incision with a separate needle pass through the adjacent intact skin to enter the incision and exited from the wound through a separate needle pass again through the intact adjacent skin (external intradermal suturing) (Figures 1B and 2).

Randomization was performed to determine on which upper eyelid the suture was entering and leaving the wound margins internally and on which upper eyelid externally. After the operation, cooling packs were applied to both eyelids. The sutures were removed after 5 to 7 days.

A plastic surgeon not involved in the treatment of this series of patients assessed the presence of focal inflammation and suture abscesses 1 week and 6 weeks after surgery. This was done by recording “yes” or “no” for the suture thread entrance and exit sites, respectively, medially and laterally at the upper eyelid wound. Standardized photographs were taken at the postoperative visits. Furthermore, patients compared the amount of erythema and edema at the medial wound margins of both their upper eyelids (externally vs internally sutured). Results of both suture techniques were compared using the McNemar test.

Results

In total, 34 patients were included in the study, 2 males and 32 females, with an age ranging from 35 to 68 years (mean, 51.5 years). Because of the lack of medical records information, 2 patients were excluded 1 week postoperatively, resulting in 32 patients.

At the 1-week follow-up, there were 12 medial suture abscesses (e.g., Figure 3) among the wounds closed with an external intradermal suture (40%) compared with 4 suture abscesses seen with the internal intradermal closure (13.3%) ($p = .021$) (Table 1). After 1 week, medial wound erythema was present in 14 externally sutured upper eyelids (48.3%) as compared with 6 upper eyelids internally sutured (20.7%) ($p = .021$). Edema was present at the medial wound margin in 17 externally sutured upper eyelids (58.6%) compared with only 9 internally sutured upper eyelids (31.0%) ($p = .021$). After 6 weeks, almost all erythema, edema, and suture abscesses

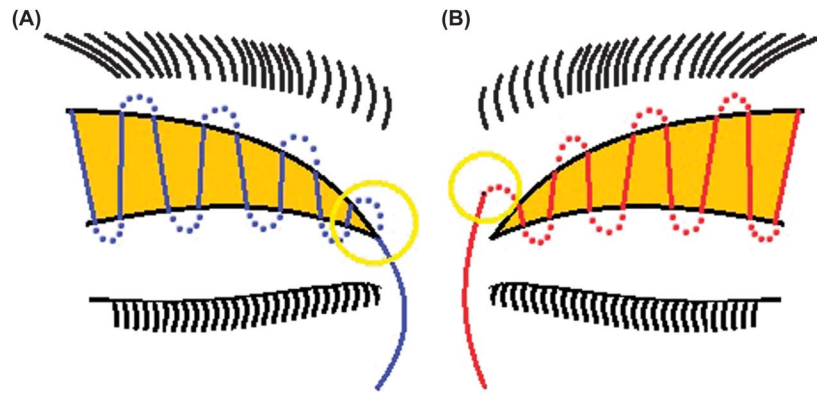


Figure 1. Subcuticular suturing of the wound margins. (A) Internal technique: the suture starts (and ends) directly in the margins of the wound. (B) External technique: the suture enters (and leaves) the intact skin close to the margins of the wound.

had resolved spontaneously and no significant difference was found anymore between the internal and external suture technique. The incidence of erythema, edema, and suture abscesses at the lateral aspect of the blepharoplasty incision was low and not statistically different at both 1- and 6-week postoperative visits.

Discussion

This study clearly demonstrates that the method used to close the upper blepharoplasty wound can affect the rate of recovery. Wounds closed with an internal intradermal suture showed significantly less medial wound inflammation 1 week after surgery compared with wounds closed with an externally started intradermal suture. This effect was only seen at the medial aspect of the wound. There was no difference in focal inflammation, or suture abscess

formation at the lateral aspect of the blepharoplasty wounds.

Sutures are a foreign material and, although some sutures incite a more brisk inflammatory response than others, all suture materials will induce a foreign body reaction to some degree. This usually manifests as redness, and/or sterile pustules along epidermal suture lines.⁵

The difference between the medial and the lateral sides of the upper eyelid skin, and also the other sites of wound closure, could be explained by either thinness of the skin at the medial canthus and thereby rapid wound healing, in combination with ingrowth of epidermal cells along the suture thread. This difference can also be explained by the fact that the suture always

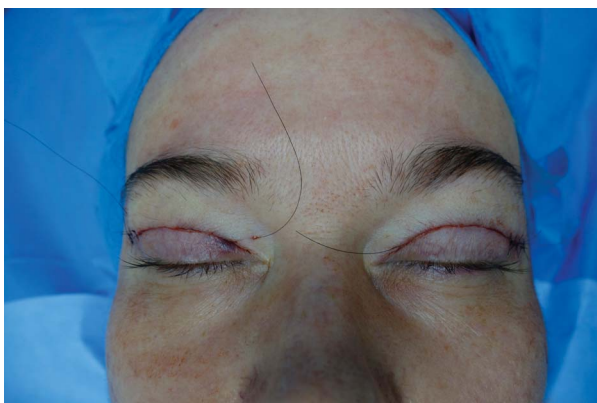

Figure 2. External intradermal suturing (the right upper eyelid) versus internal intradermal suturing (the left upper eyelid) after upper blepharoplasty.

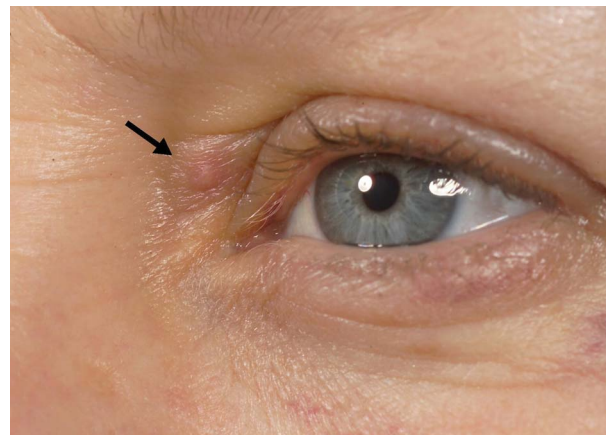


Figure 3. A suture abscess (arrow) on the medial wound margin of the left upper eyelid 1 week after using the external suture technique in upper blepharoplasty.

TABLE 1. Presence of Erythema, Edema and/or Suture Abscesses After 1 Week and 6 Weeks on Medial and Lateral Wound Margins, Using Internal and External Suture Techniques

	After 1 Week		After 6 Weeks	
	Medial Side	Lateral Side	Medial Side	Lateral Side
Internal suture, n (%)				
Erythema	6 (20.7)*	2 (7.1)	0	3 (11.1)
Edema	9 (31.0)*	2 (7.1)	2 (7.4)	1 (3.7)
Abscess	4 (13.3)*	1 (3.4)	0	0
External suture, n (%)				
Erythema	14 (48.3)	3 (10.3)	0	2 (7.4)
Edema	17 (58.6)	4 (13.8)	3 (11.1)	1 (3.7)
Abscess	12 (40)	1 (3.3)	1 (3.7)	0

*Significantly less compared with the external suture technique ($p = .021$).

starts at the medial side and leaves the wound at the lateral side (either through the wound or by puncturing). This prevents introduction of epidermal cells inside the wound or puncture site at the lateral side.

Based on this study, the authors recommend that when closing the upper blepharoplasty wound with a subcuticular closure, the suture be started internally. Since the evaluation of the results of this study, the authors have routinely used this method of internal suturing. The authors have observed very low incidence of inflammation or suture abscesses, which were more common before the study.

Acknowledgments The authors thank Sophie Post for her editorial assistance.

References

- Morax S, Touitou V. Complications of blepharoplasty. *Orbit* 2006;25:303–18; Review.
- Pacella SJ, Codner MA. Minor complications after blepharoplasty: dry eyes, chemosis, granulomas, ptosis, and scleral show. *Plast Reconstr Surg* 2010;125:709–18.
- Oestreicher J, Mehta S. Complications of blepharoplasty: prevention and management. *Plast Surg Int* 2012;2012:252368.
- van der Lei B, Timmerman IS, Cromheecke M, Hofer SO. Bipolar coagulation-assisted orbital (BICO) septoblepharoplasty: a retrospective analysis of a new fat-saving upper-eyelid blepharoplasty technique. *Ann Plast Surg* 2007;59:263–7.
- Kouba DJ, Moy RL. Complications of reconstructive surgery. In: Nouri K, editor. *Complications in dermatologic surgery*. Philadelphia: Elsevier; 2008; pp. 82–83.

Address correspondence and reprint requests to: Berend van der Lei, MD, PhD, Department of Plastic Surgery, University Medical Center Groningen, BB81, PO Box 30.001, 9700 RB, Groningen, the Netherlands, or e-mail: b.van.der.lei@umcg.nl